

Sandblasting with Al₂O₃ Powder in Dental Medicine

DANIELA JUMANCA¹, ATENA GALUSCAN^{1*}, TEODORA STEFANESCU², ADINA DUMITRACHE³

¹University of Medicine and Pharmacy Victor Babes, Faculty of Dentistry, Department of Preventive Dentistry, Community and Oral Health, 2 Eftimie Murgu Sq., 300041, Timisoara, Romania

²University of Oradea, Faculty of Medicine and Pharmacy, 10, 1 Decembrie Sq., 410073, Oradea, Romania

³University of Medicine and Pharmacy Carol Davila Bucharest, Faculty of Dentistry, Department of Oral Health, 8 Eroii Sanitari, 050474, Romania

Minimally invasive dental medicine is a novel trend, increasingly accepted by many practitioners and extension for prevention has gradually been abandoned, being replaced by increasingly conservative interventions. Air Abrasion was developed in 1945 by RB Black who started to investigate alternative pseudo-mechanical methods for the removal of dental tissue by bombarding it with a high-speed particulate flow: aluminium oxide. In the present study, we used 14 teeth extracted for orthodontic purposes or due to periodontal disease. We only selected teeth with early carious lesions (cavitory or non-cavitory), located proximally, cervically or on the occlusal surfaces of pits and fissures. Teeth were sandblasted with the RONDOflex plus (KaVo) equipment which uses the principle of hydro-sandblasting (water sandblasting) 50 µm powder. In the most cases the incipient proximal, cervical or occlusal carious processes were successfully removed, resulting in a small cavity, with bevelled margins and with the surface conditioned for composite application. In two cases, the carious process was only partially removed by Air Abrasion which showed the ineffectiveness of sandblasting in cases where the removal of healthy dental hard tissue needs to be removed. For the complete removal of the carious process, cavity preparation with the diamond drill was required, or, alternatively, opening the occlusal relief with the turbine, followed by sandblasting.

Keywords: sandblasting, aluminium oxid, Air Abrasion, Incipient carious lesion, minimal invasive dentistry

Minimally invasive dental medicine is a novel trend, increasingly accepted by many practitioners and *extension for prevention* has gradually been abandoned, being replaced by increasingly conservative interventions.

Starting with the invention and use of rotative instruments, the surgical treatment of carious lesions was followed by the removal of considerable amounts of dental structures. Recently, new techniques for the removal of carious lesions are being developed in an attempt to minimise excessive tissue loss [1].

Despite the fact that, worldwide, dental caries has decreased in industrialised and developed countries, it has increased in underdeveloped countries where the access to dental practices is difficult and oral hygiene education is virtually absent. Moreover, dental caries remains a general health problem even in developed states as it is present in underpopulated areas with limited or no access to preventive treatment regimens [2, 3].

The techniques used to remove carious lesions have evolved very much since 1893 when GV Black proposed the principle of *extension for prevention*. During recent years, together with adhesive restoration materials and the development of the minimally invasive design of cavities, the widely accepted principle is discussed and considered an excessively destructive method for the removal of carious lesions. The latest theories on rational dentine removal are starting to question the amount of tissue to be excavated in order to successfully treat a carious lesion [4].

During the process of removal of the affected tissue, one cannot be always sure at what point in time excavation should be stopped, in the absence of any objective clinical marker. The clinician tends to decide based upon tissue consistency, while a researcher might use the fluorescence of carious lesions to detect an in vitro objective, reproducible

histologic marker allowing relevant clinical comparisons between clinical excavation techniques to be used [4].

Histologic studies helped us to formulate the idea that a dental caries is not only a mere progressive demineralization but an alternative destruction and repair process. Studies on these lesions, performed on freshly extracted odontal structures, aided by a series of new exploration methods, brought novel information and shed a different light some unknown facts helping to some conclusions with a benefic impact on therapies [5].

Experimental part

Material and method

In order to remove the affected tissue, the clinician has more options, each with specific advantages and disadvantages (table 1).

Air Abrasion was developed in 1945 by RB Black who started to investigate alternative pseudo-mechanical methods for the removal of dental tissue by bombarding it

Table 1
CLASSIFICATION OF EXCAVATION TECHNIQUES FOR DENTAL TISSUES

| CATEGORY | TECHNIQUE |
|-----------------------|---|
| MECHANIC ROTATIVE | HAND PIECE + DRILL |
| MECHANIC NON-ROTATIVE | BLACK, AIR ABRASION, SONIC-ABRASION INSTRUMENTS |
| PHOTO-ABLATION | LASER |

* email: atedent@yahoo.com; Tel: 0256204950

with a high-speed particulate flow (aluminium oxide Al_2O_3) [6].

Depending on the abrasive powder used, this technique has the ability to effectively sandblast both enamel and healthy dentine. There are several parameters which can be modified in order to adjust sandblast characteristics: the type and size of abrasive particles – the higher these two features, the more kinetic energy will be transferred, resulting in a more rough surface; the speed of the particles adjusting air pressure, the distance between the nozzle and the sandblasted dental surface and the duration of sandblasting play important roles in adjusting the efficiency – once speed reduced, there will also occur a decrease of the kinetic energy transferred to the surface, with a diminished effect [7-9].

This method for preparing dental structures seems to dramatically reduce heat and vibrations generated by rotative drilling resulting in relatively painless procedures. There are reports indicating non-significant differences in pulp response to the Air Abrasion technique as compared to rotative drilling combined with large amounts of water.

The Air Abrasion technique has been used in various applications in the field of restorative dental medicine, such as stain and tartar removal, minimal preparations, conditioning of prosthetic blunts and an aid in sealing procedures, with the conditioning of grooves and pits. These applications do not include the removal of affected, soft dentine tissue using abrasive aluminium powder.

In 1952 research conducted by Van Leeuwen and Rossano, using over 40 μm diameter particles were performed, this size being much above the level considered harmful if inhaled. They concluded that based on the size and composition of the particle cloud formed as a result of the Air Abrasion technique, there is no danger for the patient or for the medical staff [10]. Today, this technique is US FDA approved for the clinical use of aluminium particles with a minimum diameter of 27.5 μm .

More in-depth studies on powders indicated that less hard powders (e.g. polycarbonate resins) are more selective in removing amelo-dentine tissues, only removing the portions with equivalent hardness, thus bringing up the conservative idea, as they leave the healthy amelo-dentine tissue practically untouched [11, 12]. These factors, combined with protecting the neighboring tissues by using the rubber dam and effective aspiration put the Air Abrasion

technique at the top of alternatives for the instrumental approach of cavities.

The problem raised by this technique is that it lacks precision. All these remove carious dental tissue with various levels of efficiency but the major drawback is the uncertainty regarding the capacity to discriminate between soft, infected, necrotic tissue and healthy or reversibly affected tissues, which may be preserved. If no clear distinction is possible, there will always be a chance of excessive preparation with minimal control over the quantity and quality of preparation. It is important to take into account the efficacy and effects of these techniques (table 2).

Sandblasting may be best described as a pseudo-mechanical process for the removal of hard dental tissue. Terms such as *micro-sandblasting* or *kinetic preparation* have been used to describe cavity preparation by sandblasting. Even though the basic sandblasting procedure remained practically unchanged, it has seen a revival not due to changes in equipment but due to improvements in adhesion, restorative materials, isolation and aspiration [13, 14].

Studies describe that adhesion to enamel and dentine surfaces prepared by the Air Abrasion method is significantly superior to cases when surfaces are prepared by conventional methods (mechanical preparation by diamond or blade drilling or by etching) [15-17].

In this study, we used abrasive aluminium oxide powder, an inorganic compound with the chemical formula Al_2O_3 . It is generally used for the production of aluminium. Aluminium is the most widespread metal in nature and it enters in the composition of clays. It is the third most spread element after oxygen and silicium. Aluminium is closely connected to oxygen and silicium forming aluminosilicates which enter into the composition of the earth and which, after degradation, generate kaolinite-based clays. It is usually found in its crystalline-polymorphic phase $\alpha\text{-Al}_2\text{O}_3$, as corundum, a variety which forms precious gems: rubies and sapphires. Al_2O_3 is important in the production of metallic aluminium, as an abrasive due to its hardness and also as a refraction material due to its high melting point (table 3) [18]. It is important to keep in mind that aluminium oxide is an amphoteric substance i.e. it has the capacity to react both with acids, such as chlorhydric acid, and with bases, such as sodium dioxide, reacting as an

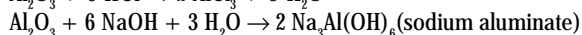

Table 2
CHARACTERISTICS OF DENTAL TISSUE EXCAVATION TECHNIQUES

| Method | Healthy enamels | Healthy dentine | Carious enamel | Carious dentine | Notes |
|-----------------------|-----------------|-----------------|----------------|-----------------|--|
| Manual excavators ale | - | - | + | ++ | Black instruments |
| Rotative preparation | +++ | +++ | +++ | +++ | Drill, counter-angle piece |
| Air Abrasion | +++ | +++ | ++ | + | Depends on abrasive powder |
| Sono Abrasion | - | + | + | ++ | Requires additional types of preparation |
| Laser | + | + | + | + | Depends on intensity, puls, |

| Characteristics | Value |
|-------------------------------|--|
| Thermal expansion at 25 °C | $7.1 \cdot 10^{-6} \text{ K}^{-1}$ |
| Thermal conductivity at 25 °C | $0.46 \text{ J.cm}^{-1}.\text{s}^{-1}.\text{K}^{-1}$ |
| Dielectric constant at 25 °C | 10.6 |
| Resistivity at 14 °C | $10^{19} \Omega.\text{cm}$ |

Table 3
CHARACTERISTICS OF ALUMINIUM OXIDE

acid with a base and as a base with an acid, by neutralization of the other substance with production of a salt.



The most commonly encountered form of crystalline aluminium is corundum. Oxygen ions form a hexagonal structure with aluminium ions, occupying two-thirds of the octahedral interstitial sites.

Using the procedure in dental medicine

Sandblasting in the field of dental medicine (found in literature as Air Abrasion) may be used to clean dental surfaces (plaque, stains) but it may also be used to remove affected tissue in carious lesions. Surprisingly, sandblasting is not such a new field in dentistry. The history of sandblasting in dental medicine records, as early as 1940, a company named S.S White Dental Manufacturing Company, which launched a device on the market under the name of Airdent. The fierce battle between Airdent and the high-speed air rotor (dental drill), was won by the latter [19]. Despite promising results, the former did not gain popularity due to three main factors. Firstly, by sandblasting one could not prepare a cavity with well-defined walls and margins and restoration material in those days (mostly amalgam) did not allow any other manner of preparation because adhesion had not yet been introduced. Secondly, the introduction of the handpiece, air drill, during the late 1950s, made the preparation of conventional cavities more effective by saving time. Thirdly, as high power aspiration had not yet been developed, the evacuation of residual powders was a true ordeal for the patient.

In the present study, we used 14 teeth extracted for orthodontic purposes or due to periodontal disease. We only selected teeth with early carious lesions (cavitory or non-cavitory), located proximally, cervically or on the occlusal surfaces of pits and fissures. In early childhood most caries appear on the occlusal surface. In adult

patients, most caries develop in the interproximal and cervical area. As a result of gingival recession and root surface exposure under an improper oral hygiene, the decay appears frequently on the root at the cemento - enamel junction or at the cervical level of the crown [20].

After extraction, teeth were washed and kept in sodium saline until the moment of use. Fourteen teeth were selected and divided into 3 groups as follows (fig.1-14):

- incisors: I1; I2; I3; I4;
- premolars: P1; P2; P3; P4;
- molars: M1; M2; M3; M4; M5; M6;

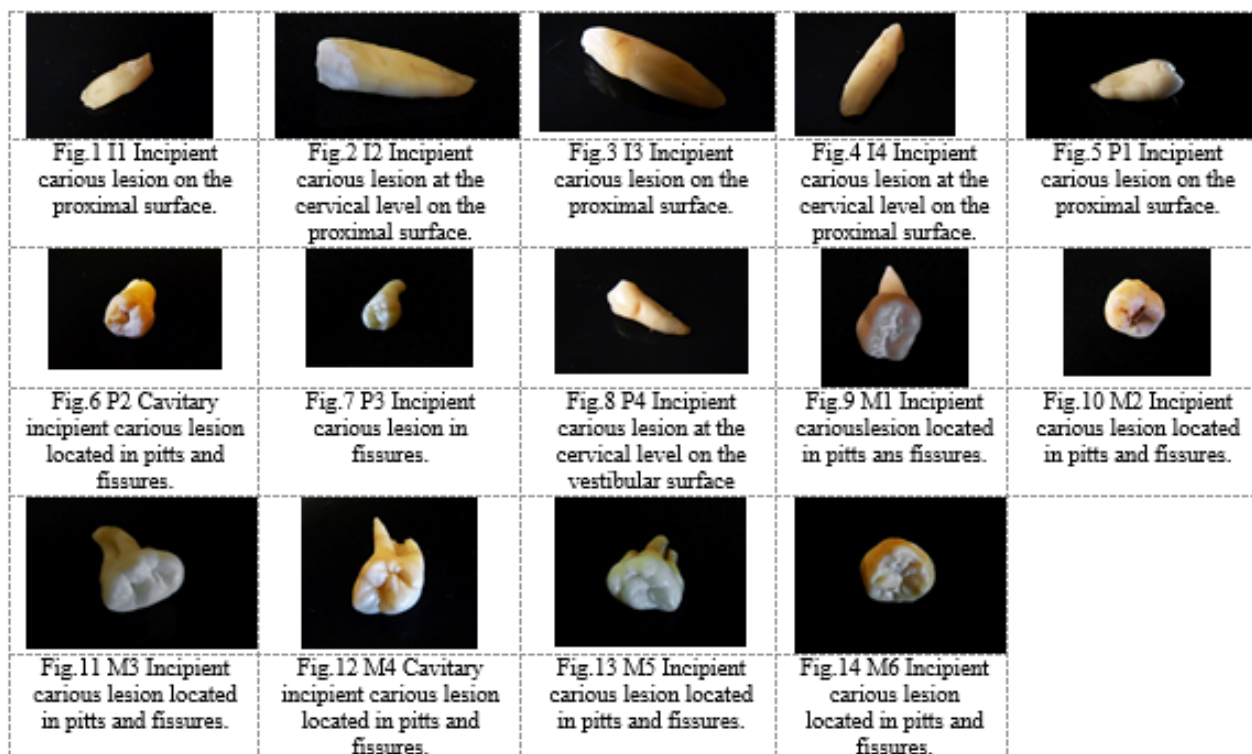
Teeth were sandblasted with the RONDOflex plus (KaVo) equipment which uses the principle of hydro-sandblasting (water sandblasting) 50µm powder. Water cooling is a real advantage in the case of in vivo preparation as it protects the integrity of the dental pulp and diminishes the patient's discomfort.

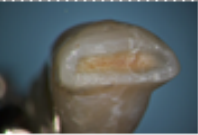



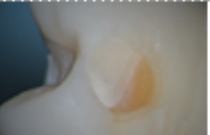
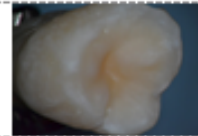
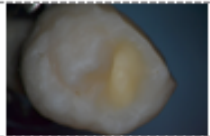

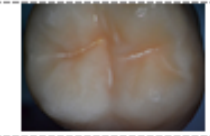

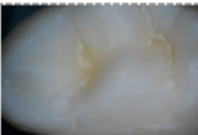
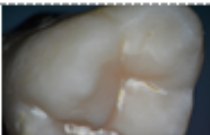
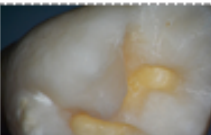
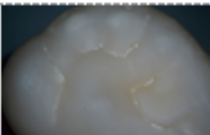
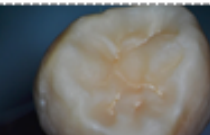
In order to compare the Air Abrasion technique with the classical preparation by drilling, all carious lesions were initially treated by sandblasting and later, in cases where this method did not bring satisfactory results, the rotative treatment was also used. In the case where sandblasting proved inefficient in the complete removal of the carious process, we prepared the cavity using a globular drill, blue code, 0.8 mm, adapted in the turbine. In all cases, the removal of the carious process was performed as conservatively as possible, preparing the tooth for etching (including beveling).

Results and discussions

At I1 the carious process was removed from the start with the diamond drill inserted into the turbine in order to correctly examine the difference between turbine and Air Abrasion preparations in terms of hard dental substance loss (fig. 15).

In teeth I2, I3, I4, P1, P2, P3, P4, M1, M3, M5 and M6, the incipient proximal, cervical or occlusal carious processes were successfully removed by the Air Abrasion technique with Al_2O_3 50µm powder, resulting in a small cavity, with bevelled margins and with the surface conditioned for composite application (fig. 16-23, 25, 28 and 29).



| | | | | |
|---|---|---|---|--|
|  |  |  |  |  |
| Fig.15 I1 Completely removed carious process with remaining bevelled margins. | Fig.16 I2 Completely removed carious process with Air abrasion technique, with remaining bevelled margins and conditioned surfaces. | Fig.17 I3 Completely removed carious process with Air abrasion technique, with remaining bevelled margins and conditioned surfaces. | Fig.18 I4 Completely removed carious process with Air abrasion technique, with remaining bevelled margins and conditioned surfaces | Fig.18 P1 Completely removed carious process with Air abrasion technique, with remaining bevelled margins and conditioned surfaces. Enamel/dentine junction visible. |
|  |  |  |  |  |
| Fig.20 P2 Completely removed carious process with Air abrasion technique, with remaining bevelled margins and conditioned surfaces. | Fig.21 P3 Completely removed carious process with Air abrasion technique, with remaining bevelled margins and conditioned surfaces. | Fig.22 P4 Completely removed carious process with Air abrasion technique, with remaining bevelled margins and conditioned surfaces. | Fig.23 M1 Completely removed carious process with Air abrasion technique, with remaining bevelled margins and conditioned surfaces. | Fig.24 M2 Incompletely removed carious process. Inefficient in areas with pronounced anatomy. |
|  |  |  |  |  |
| Fig.25 M3 Completely removed carious process with Air abrasion technique, with remaining bevelled margins and conditioned surfaces | Fig.26 M4 Partially removed carious process revealing the incapacity of the Air abrasion technique in areas with healthy tissue. | Fig.27 M4 Completely removed carious process with remaining bevelled margins | Fig.28 M5 Completely removed carious process with Air abrasion technique, with remaining bevelled margins and conditioned surfaces. | Fig.29 M6 Completely removed carious process with Air abrasion technique, with remaining bevelled margins and conditioned surfaces. |

In M2 and M4 teeth, the carious process was only partially removed by Air Abrasion which showed the ineffectiveness of sandblasting in cases where the removal of healthy dental hard tissue needs to be removed. In these cases, incipient caries situated in the depth of occlusal grooves and pits were involved (fig. 24), which were partially covered by healthy enamel. For the complete removal of the carious process, cavity preparation with the diamond drill was required (fig. 27), or, alternatively, opening the occlusal relief with the turbine, followed by sandblasting.

The reemergence of the Air Abrasion technique, together with novel restoration materials, gave a new dimension to the notion of minimally invasive dental medicine. Micromechanical adhesion of restoration materials to dental surfaces by minimally invasive preparation techniques removes the need for conventional preparation which follows the cavity design introduced G. V. Black. Dental medicine is able to offer truly conservative treatments. Together with benefits brought by this technique, the dentist is responsible for the education of patients regarding prevention and maintaining oral health. Thorough knowledge and clinical experience support the dentist in using this technique in many of the encountered clinical situations.

Despite numerous advantages, the method is not effective for coarse carious tissues because the abrasive

effect is diminished by soft, sticky tissues. In such cases, we shall have to use hand instruments or conventional rotative pieces to help remove these structures, and then use sandblasting.

Conclusions

- the Air Abrasion technique can be successfully used for the removal of incipient carious lesions located on proximal, cervical or occlusal dental surfaces;
- it is a minimally invasive technique, the loss of hard dental substance is reduced as compared to cavity preparation by rotative instruments;
- in cases where this technique is ineffective (such as incipient caries in deep grooves and pits), the carious process can be revealed with rotative instruments, followed by preparation by sandblasting, to limit as much as possible the sacrifice of healthy hard tissue;
- after conventional preparation, the Air Abrasion technique may be used to finalise and condition surfaces [21];
- the conventional treatment of caries involves the use of rotary tools at high speed of turbine to access the carious lesion, and at a low-speed handpiece in order to remove the decrepit dentin. Using the bent piece is very unpleasant for many patients, especially due to the noise and the vibrations that occur [4].

References

1. BANERJEE, A., WATSON, T.F., KIDD, E.A.M., Dentine caries excavation: a review of current clinical techniques. *British Dental Journal* 188; 476 - 482, 2000
3. HOROWITZ, A.M., Introduction to the Symposium on Minimal Intervention Techniques for Caries, *Journal of Public Health Dentistry* Volume 56, Issue 3, pages 133-134, September 1996
3. PODARIU, A., JUMANCA, D., MUNTEAN, R., GALUSCAN, A., OANCEA, R., *Tratat de medicina dentară preventivă*. Timisoara: Ed. Waldpress; 2006.
4. GALUSCAN, A., JUMANCA, D., PODARIU, A., ARDELEAN, L., RUSU L.C., Evaluation by Fluorescent Light of Chemo-Mechanical Treatment of Caries Removal Using Carisolv™. *Rev. Chim. (Bucharest)*, **63**, no. 9, 2012, p. 949
5. BOLD, A., CARLIGERIU, V., CHERLEA, V., *Cariologie si Odontoterapie restauratoare* 2001
6. BLACK, R.B., Technic for non-mechanical preparations of cavities and prophylaxis. *J Am Dent Assoc* 1945; 32: 955-965.
7. ANDERSON, D.J., VAN PRAAGH G., Preliminary investigation of the temperatures produced in burring. *Br Dent J* 1942; 73: 62-64.
8. NORTON, H.D., The airdent machine: some personal observations. *Br Dent J* 1951; 91: 268-269.
9. WHITE, H.D., PEYTON F.A., Effects of air abrasive in prophylaxis. *J Am Dent Assoc* 1954; 49: 155-163.
10. VAN LEEUWEN, M.J., ROSSANO A.T., Dust factors involved in the use of the airdent machine. *J Dent Res* 1952; 31: 33-34.
11. HORIGUCHI, S., YAMADA, T., INOKOSHI, S., TAGAMI, J., Selective caries removal with air abrasion. *Op Dent* 1998; 23: 236-243.
12. BANERJEE, A., KIDD, E.A.M., WATSON, T.F., Scanning electron microscopic observations of human dentine after mechanical caries excavation. *J. Dent*: in press.
13. ALEX, G., Universal adhesives: the next evolution in adhesive dentistry?, *Compend Contin Educ Dent*. 2015 Jan; 36 (1):15-26; quiz 28, 40.
14. CHRISTENSEN, G., Cavity preparation: Cutting or abrasion? *J Am Dent Assoc*. 1996;127:1651
15. LAURELL, K., LORD, W., BECK, M., Kinetic cavity preparation effects on bonding to enamel and dentin, *J Dent Res*. 1993; 72:283.
16. KEEN, D.S., VON FRAUHOFFER, J.A., PARKINS, F.M., Air-abrasive etching: Composite bond strengths *J Dent Res*. 1994; 73:131.
17. BERRY, E.A., WARD, M., Bond strength of resin composite to air-abraded enamel. *Quintessence Int*. 1995, 26:559-62. [PubMed]
18. BORSATTO, M.C., CATIRSE, A.B., PALMA DIBB, R.G., NASCIMENTO, T.N., ROCHA, R.A., CORONA, S.A., Shear bond strength of enamel surface treated with air-abrasive system. *Braz Dent J*. 2002;13:175-8.
19. *** <http://www.thedentalcheck.com/sandblasting-for-teeth/#sthash.Ab9nAXvY.dpuf>
20. JUMANCA, D., SILVASAN, H., GALUSCAN, A., PODARIU, A.C., ARDELEAN, L., RUSU, L.C., The Use of Hybrid Ionomer-composite Geristore in Restorations, *Rev. Chim. (Bucharest)*, **63**, no. 10, 2012 p. 1023
21. ROEDER, L.B., BERRY, E.A., YOU, I., POWERS, J.M., Bond strength of composite to air-abraded enamel and dentin. *Oper Dent*. 1995; 20:186-90.

Manuscript received: 21.03.2016